

Grafting Fresh Extraction Sockets

George Beck, D.D.S., Pueblo, Colorado

A 51-year old patient presented in my office with the chief complaint of both upper and lower anterior teeth being loose, some pain and tender to percussion. The #8 tooth had been endodontically treated years ago and presently was draining. The patient was wearing both upper and lower removable chrome casting and acrylic partials that were unsatisfactory to the patient.

After both clinical and radiographic evaluation, it was determined the teeth were not salvageable and two different treatment options were presented to the patient, both of which included extraction of the remaining teeth (Figure 1). The first option offered to the patient was removal of the natural teeth and full upper and lower removable dentures. The second treatment plan for consideration was endosseous implants in both arches allowing for fixed prosthetic reconstruction.

Although the patient was receptive to implant therapy, the financial considerations of the treatment plan made immediate acceptance of both upper and lower reconstruction with implants impossible. However, a compromise was reached that the construction of an implant-supported full lower denture would precede the final restorations of the maxillary arch.

Understanding the patient's desires and financial situation, it was agreed that 5 implants would be placed in the lower anterior for construction of a fixed removal lower denture. The upper arch would receive conventional removable denture until such time as endosseous implants were feasi-

ble. The first step of the long-term treatment plan, extraction of the existing natural dentition, was scheduled. Primary impressions were taken for fabrication of temporary removable upper and lower dentures to wear during the healing and treatment phase.

The patient presented for extraction of teeth #7-10 and #20-27. The patient was anesthetized with lidocaine and Marcaine®. Re-evaluation of the dentition confirmed severe periodontal involvement of teeth #20-27 and moderate to severe involvement of teeth #7-10. Since #8 had been previously treated endodontically, there was concern that during the extraction procedure, the cortical plate would fracture. Maintaining the cortical plate offers a much higher success rate for the grafted socket. If maintained, the socket remains a 5-wall defect with excellent opportunity for bone regeneration. If the cortical plate fractures, the socket becomes a 3-wall defect.

The extraction of the maxillary anterior teeth was atraumatic, including #8, which was avulsed without fracture (Figure 2). The sockets were evaluated and prepared for grafting. *OsteoGraf*®/LD-300, (CeraMed Dental, L.L.C., Lakewood, Colorado) synthetic resorbable hydroxylapatite was chosen as the ideal bone replacement graft material for this case. Due to the uncertainty of the patient's treatment plan for this arch, it was imperative to preserve the

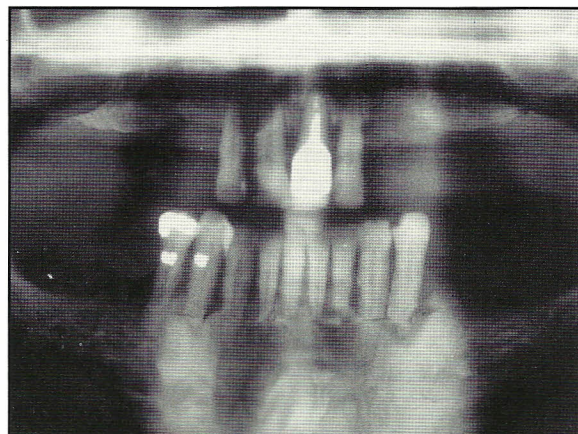


Figure 1. Preoperative radiograph.

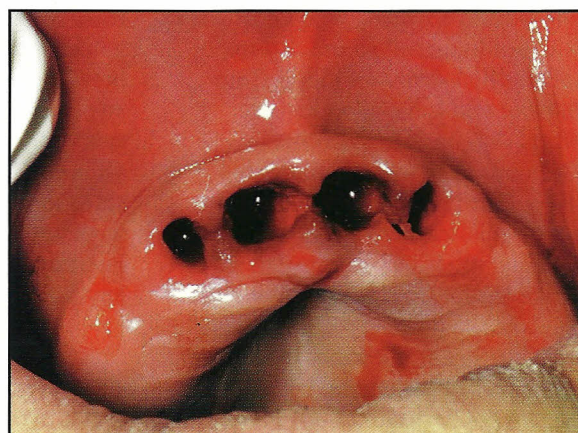


Figure 2. Teeth extracted without fracture.

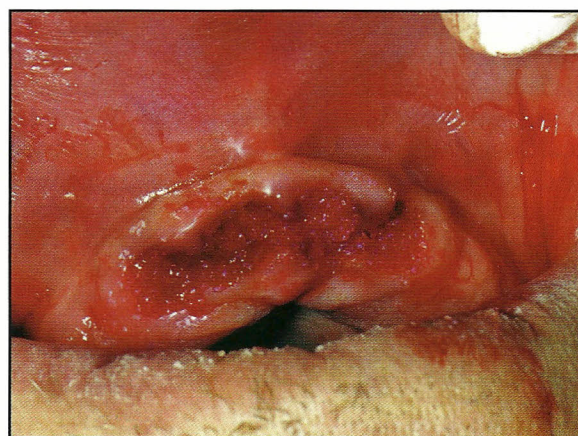


Figure 3. Sockets grafted with *OsteoGraf*®/LD-300.

Case study

buccal / lingual width of the arch. *OsteoGraf/LD-300* will offer ridge preservation to the arch and yet allow a secondary procedure such as endosseous implants at a later date.

The graft material was hydrated with a sterile saline solution just prior to placement. Once hydrated, the synthetic resorbable hydroxylapatite was loosely but firmly packed into the sockets using a #23 periodontal elevator 3. After all four maxillary sockets were packed with the graft material, Gelfoam® #4 was placed over the grafted sockets. The Gelfoam was not hydrated so the dry material could absorb any blood from the site and have a hemostatic effect (Figure 3). With the Gelfoam in position, containing the graft material, suturing was accomplished with single interlocking stitching, crossing to stabilize the Gelfoam (Figure 4, 5).

The lower anteriors were then extracted atraumatically. Due to the severe periodontal involvement, the teeth were easily removed. There was severe bone loss around the existing teeth leaving the sockets only millimeters deep. Grafting these areas would not have been practical. The patient is scheduled for endosseous implants in this area and there is adequate bone height and width to accommodate the implants. At the time of implant

placement, an alveoplasty will be done.

Upper and lower temporary immediate dentures had been fabricated prior to the surgical appointment. The dentures were seated and the patient instructed these prostheses were for esthetics only and not functioning dentures (Figure 6).

The patient was discharged with post extraction home care instructions that included gentle pressure with gauze sponge to control bleeding, ice bag to control swelling and to begin warm salt water rinsing after the first 48 hours have passed. A prescription for amoxicillin for 6 days was given and the patient instructed to take Tylenol for any pain and/or discomfort.

Grafting extraction sockets prevents bone resorption. If not prevented, bone will continue to resorb during the life of the patient making it difficult to maintain fit, function, and esthetics of any prosthesis. The time involved to graft fresh extraction sites is minimal compared to the time required to re-graft and regenerate bone to an atrophied ridge for esthetics and/or endosseous implants. ♥

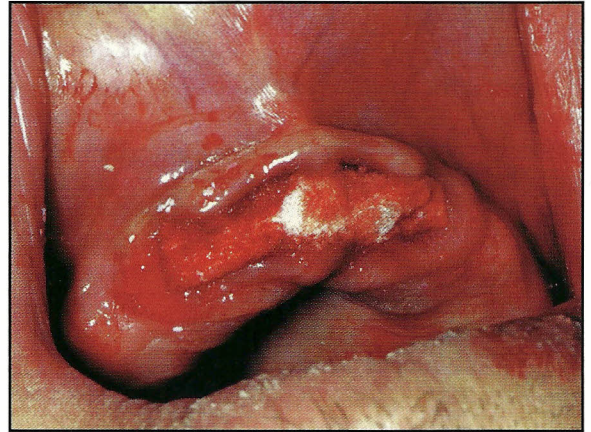


Figure 4. Gelfoam® in position for containment.

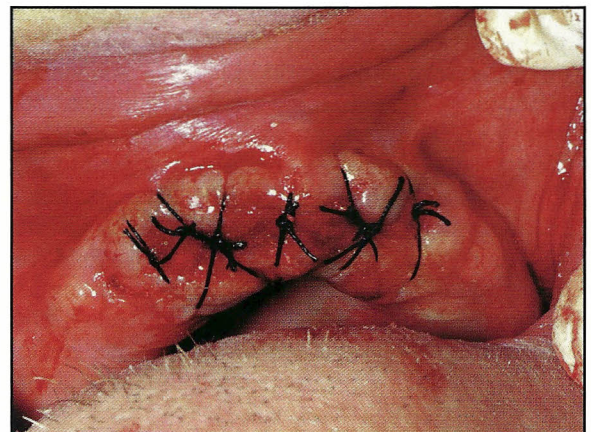


Figure 5. Single interlocking sutures.

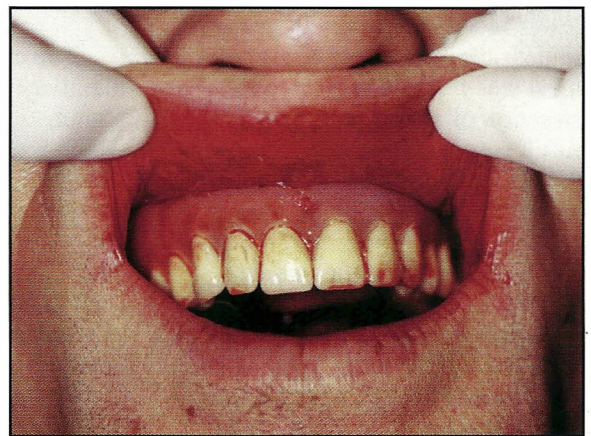


Figure 6. Temporary non-functioning denture.

solutions through science...

cera med

D E N T A L

12860 West Cedar Drive
Lakewood, CO 80228
800 426-7836
303 985-0800